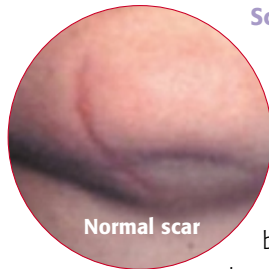


Practical Scar Care

BY Deepak Mistry

The first consideration in scar treatment is prevention. Events that occur during the management of the open wound are influential. Providing a healthy environment for the wound to heal is most important.

Once the wound is closed, treatment can begin to prevent too much scarring. Over the past two decades, several new therapeutic approaches to scar management have been reported. These new approaches promise to add substantially to existing therapeutic approaches. This article attempts to summarize most of these new concepts.

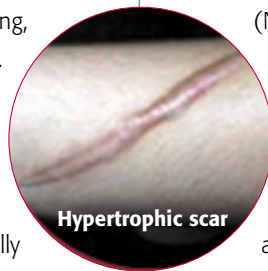


Normal scar

Scar Information

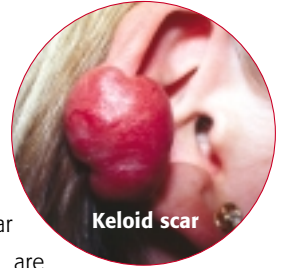
Scars are produced as the result of wound healing. Instead of replacing damaged tissue with regenerated identical tissue, human and most animal wounds are healed by filling the wound with scar. In theory, this allows faster yet less perfect wound healing. However, today most people would rather their wounds heal without scarring, even if this requires more time.

Scars can be limiting and disfiguring, particularly when the injury is extensive. The amount of scar produced is a consequence of many factors, including the extent of traumatized tissue around the wound, how long the wound remains open, the anatomic location, and genetically determined healing factors. When more scar forms than is desirable, the scar is considered hypertrophic. Initial rapid growth followed by gradual fading and shrinkage characterize hypertrophic scars over several years. This often leads to widened, unattractive skin defects.



Hypertrophic scar

Some individuals have a genetically inherited disease characterized by extreme and excess scar production. These scars are



Keloid scar

called keloid scars, and they are very different than hypertrophic scars—although they do share some common features. Keloid scars tend to become much larger than the original wound. They usually persist and reoccur after surgical excision.

Anti-inflammatory Agents

Limiting inflammation is paramount to scar reduction. Inhibition of inflammation using corticosteroid injections is one of the oldest and most established approaches to scar management. The broad effects include inhibition of protein synthesis, including collagen and other extracellular matrix proteins. However, the adverse side effects of repeated injections as well as the frequent occurrence of skin depigmentation are major drawbacks to this approach. Steroids are not effective for treatment of older, asymptomatic scars that are less metabolically active.

Although non-steroidal anti-inflammatory drugs (NSAIDs) have been used to prevent internal scarring in arthritis for decades, they have only recently been used for hypertrophic and keloid scar management. Our experience suggests that the newer type-2 cyclo-oxygenase inhibitors are very effective in reducing symptoms of pruritus. They also seem to induce scar maturation and involution.

Salicylic acid and acetylsalicylic acid (aspirin) are powerful anti-inflammatory medications that are commonly used to treat skin inflammation-related ailments. Salicylates (two to five per cent) are com-

Deepak Mistry, BSc,

is a graduate of the University of Chicago and is currently involved in the research and development of new approaches to scar reduction at Avocet Polymer Technologies Inc.

monly used to control skin inflammation and are routinely used in acne treatment products. We have found topical salicylates to be among the most effective anti-scar agents. These agents should not be used on open wounds. Topical aspirin should be used under a physician's guidance because some patients, particularly asthmatics, may develop hypersensitivity.

Anti-histamines are commonly used to control symptoms of scar pruritus. However, they have other important anti-scar properties. Anti-histamines, particularly the H1 blockers, inhibit the inflammatory response, resulting in reduced scar formation and increased comfort. Reducing patient itching and scratching reduces the inflammation and the scar growth rate. Finally, anti-histamines in high doses are well known to inhibit collagen synthesis.

Inhibitors of Gene Transcription

The anti-cancer drugs mitomycin-c and 5-fluorouracil inhibit population growth of cells by blocking DNA replication. A single application in the first few days after wound closure seems to be effective in scar reduction under laboratory conditions. Further investigation will be needed to determine how this approach can be used clinically.

Acceleration of Scar Degradation

While steroids and NSAIDs act to limit scar production, other strategies act to induce or accelerate scar degradation. This approach may be the best for management of older hypertrophic scars and older keloids. The rate of tissue breakdown can be increased by both pharmacologic and physicochemical means.

Occlusive Dressings

After elastic pressure wrap dressings applied to healing burn scars were observed to be effective in the reduction of scar formation, 20–24 mmHg pressure garments have become the mainstay of scar prevention. The mechanism of action of pressure dressings is unknown because they remain effective even when they lose elasticity and pressure several weeks after daily use. Measurements show a decrease in wound metabolism with an increase in collagenase activity. Drawbacks to their use are primarily related to their thermal insulation and movement restriction.

Hydrogel and silicone sheeting have been used to con-

trol scar formation. Like elastic garments, the mechanism of action is not known, but hypotheses reported in the literature include induction of scar hypoxia, increased hydration of the epidermis covering the scar and increased scar temperature. Several reports have shown that hydrogel sheeting is equally effective as silicone and has fewer adverse side effects. Hydrogel sheeting has been approved by the U.S. Food and Drug Administration (FDA) as substantially equivalent to silicone for treatment of hypertrophic scars. Hydrogels have the added advantages of use as a drug delivery vehicle as well as having a higher heat capacity for buffering scar temperature.

Surgical Removal

The most common indications for surgical removal of scars are the following: large scars that are unlikely to be substantially reduced using medical therapy within a practical timeframe; scars that harbor infection; and scar contractures that hamper movement function. Surgical revision of hypertrophic or keloid scars is associated with a high recurrence rate. Gentle surgical technique is critically important because inflamed scar tissue produces a tremendous scar response to trauma. Adjunctive measures to reduce inflammation, skin tension and other factors are essential to reduce recurrence. Use of lasers and other burning techniques for scar removal is very controversial.

In order to reduce the scar recurrence rate after surgery, effective scar control medications should be initiated pre-operatively and continued post-operatively. Our experience suggests that most patients with scars large enough to require surgical excision require both systemic COX-2 inhibitors and long-acting H1 anti-histamines to induce scar degradation and reduce recurrence. Increasingly, our experience suggests that topical application of NSAIDs to healing wounds will be the most practical approach. Trans-epidermal delivery of these agents is enhanced by the application of an occlusive barrier such as hydrogel sheeting.

Conclusion

Hypertrophic and keloid scarring can be essentially reduced to inflammation mediated dermal fibrosis, suggesting that there is much insight into effective management that can be gleaned from dermatological and rheumatologic conditions of similar pathophysiology. ☺